

ORIGINAL ARTICLE

Pathologic Antibodies to Platelet Factor 4 after ChAdOx1 nCoV-19 Vaccination

Marie Scully, M.D., Deepak Singh, B.Sc., Robert Lown, M.D.,
Anthony Poles, M.D., Thomas Solomon, M.D., Marcel Levi, M.D.,
David Goldblatt, M.D., Ph.D., Pavel Kotoucek, M.D., William Thomas, M.D.,
and William Lester, M.D.

ABSTRACT

BACKGROUND

The mainstay of control of the coronavirus disease 2019 (Covid-19) pandemic is vaccination against severe acute respiratory syndrome coronavirus 2 (SARS-CoV-2). Within a year, several vaccines have been developed and millions of doses delivered. Reporting of adverse events is a critical postmarketing activity.

METHODS

We report findings in 23 patients who presented with thrombosis and thrombocytopenia 6 to 24 days after receiving the first dose of the ChAdOx1 nCoV-19 vaccine (AstraZeneca). On the basis of their clinical and laboratory features, we identify a novel underlying mechanism and address the therapeutic implications.

RESULTS

In the absence of previous prothrombotic medical conditions, 22 patients presented with acute thrombocytopenia and thrombosis, primarily cerebral venous thrombosis, and 1 patient presented with isolated thrombocytopenia and a hemorrhagic phenotype. All the patients had low or normal fibrinogen levels and elevated D-dimer levels at presentation. No evidence of thrombophilia or causative precipitants was identified. Testing for antibodies to platelet factor 4 (PF4) was positive in 21 patients, negative in 1 patient, and equivocal in 1 patient. On the basis of the pathophysiological features observed in these patients, we recommend that treatment with platelet transfusions be avoided because of the risk of progression in thrombotic symptoms and that the administration of a nonheparin anticoagulant agent and intravenous immune globulin be considered for the first occurrence of these symptoms.

CONCLUSIONS

Vaccination against SARS-CoV-2 remains critical for control of the Covid-19 pandemic. A pathogenic PF4-dependent syndrome, unrelated to the use of heparin therapy, can occur after the administration of the ChAdOx1 nCoV-19 vaccine. Rapid identification of this rare syndrome is important because of the therapeutic implications.

From the Department of Haematology, University College London Hospitals NHS Foundation Trust (M.S., M.L.), National Institute for Health Research University College London Hospitals Biomedical Research Centre (M.S., M.L.), Special Coagulation, Health Services Laboratories (D.S.), Great Ormond Street Institute of Child Health, University College London (D.G.), and National Institute for Health Research Great Ormond Street Biomedical Research Centre (D.G.), London, the Department of Haematology, University Hospital Southampton, Southampton (R.L.), National Health Service Blood and Transplant, Bristol (A.P.), National Institute for Health Research Health Protection Research Unit, University of Liverpool, Liverpool (T.S.), the Department of Haematology, Mid Essex Hospitals, Chelmsford (P.K.), the Department of Haematology, Addenbrookes Hospital, Cambridge (W.T.), and the Department of Haematology, University Hospitals Birmingham, and Institute of Cardiovascular Sciences, University of Birmingham, Birmingham (W.L.) — all in the United Kingdom; and the Department of Vascular Medicine, Amsterdam University Medical Center, Amsterdam (M.L.). Address reprint requests to Prof. Scully at the Department of Haematology, University College London Hospitals NHS Foundation Trust, 250 Euston Rd., London NW1 2PG, United Kingdom, or at m.scully@ucl.ac.uk.

This article was published on April 16, 2021, at NEJM.org.

DOI: 10.1056/NEJMoa2105385

Copyright © 2021 Massachusetts Medical Society.

CORONAVIRUS DISEASE 2019 (COVID-19) has been associated with considerable morbidity and mortality.^{1,2} From the onset of the Covid-19 pandemic to March 2021, more than 126.8 million cases and 2.7 million deaths were documented worldwide.³

With unprecedented speed, vaccines against severe acute respiratory syndrome coronavirus 2 (SARS-CoV-2) have been licensed and used worldwide.^{4,5} Rollout of the vaccines has been uneven, but in some countries, very high levels of coverage have been achieved. In Israel, more than half the population of 9 million has received a second dose; in the United Kingdom, more than 25 million people have received at least one dose. With such widespread and rapid uptake of the vaccines, safety signals should be documented.

A safety signal of particular concern temporally associated with the administration of the ChAdOx1 nCoV-19 vaccine (AstraZeneca) has recently been described,^{6,7} involving an unusual clinical constellation of abnormal clotting, particularly cerebral venous thrombosis, and thrombocytopenia that has resulted in death in some cases. Intensive reviews of the risk of venous thromboembolism associated with vaccines against SARS-CoV-2 were conducted by both the U.K. Medicines and Healthcare Products Regulatory Agency (MHRA) and the European Medicines Agency (EMA). After their initial reviews, both agencies confirmed that the risk of venous thromboembolism associated with the vaccines was not higher than the background risk in the general population and emphasized the overwhelmingly favorable risk–benefit ratio for vaccines against SARS-CoV-2. However, although a causal association has not yet been confirmed,⁸ they have acknowledged that vaccines against SARS-CoV-2 may be associated with a rare but serious adverse event related to thrombosis, primarily cerebral venous thrombosis, and thrombocytopenia.⁹

To gain a better understanding of the described clinical syndrome of concern, we conducted a study involving 22 patients referred to a specialist hematologist for the evaluation of thrombosis and thrombocytopenia and 1 patient referred for the evaluation of isolated thrombocytopenia and a very high D-dimer level temporally associated with the administration of the first dose of the ChAdOx1 nCoV-19 vaccine. The

thrombosis events were primarily cerebral venous thrombosis but also included arterial thrombosis and more common types of venous thromboembolism, such as pulmonary embolism. We identified a novel underlying mechanism associated with the presentation. On the basis of the clinical features and subsequent laboratory findings, we propose an altered therapeutic approach and give guidance on the assessment of patients who present with this rare syndrome.

METHODS

PATIENT IDENTIFICATION

Patients were identified for the investigation of suspected vaccine-induced thrombosis and thrombocytopenia (i.e., vaccine-induced immune thrombotic thrombocytopenia, or VITT). No evidence of hereditary or acquired thrombophilia had been identified at the referring hospitals. In the 3 index patients, the decision to test for antibodies to platelet factor 4 (PF4) was based on the presence of progressive thrombosis, thrombocytopenia, and clinical features similar to those seen in patients with heparin-induced thrombocytopenia (HIT), despite the absence of exposure to heparin. Within less than 7 days, a total of 23 patients were identified for testing, including new patients who were admitted with suggestive clinical features and 3 patients who had died after a clinical course consistent with this syndrome.

ENZYME-LINKED IMMUNOSORBENT ASSAYS

Testing for anti-PF4 antibodies was performed by means of enzyme-linked immunosorbent assays (ELISAs) at six reference laboratories in the United Kingdom. Additional testing for anti-PF4 antibodies was performed by means of various techniques used locally for HIT testing at individual centers. In many cases, HIT testing with the chemiluminescence HemosIL AcuStar HIT IgG assay (Werfen) was negative but testing with an ELISA was positive. ELISAs included the Lifecodes PF4 IgG assay (Immucor) and the Asserachrom HPIA IgG assay (Stago). These assays have a normal range (median plus standard deviation) of anti-PF4 antibodies for healthy controls and a range for patients who have received heparin. The positive thresholds were based on the normal ranges (≤ 0.238 optical density units

[OD] for the Asserachrom HPIA IgG assay and <0.40 OD for the Lifecodes PF4 IgG assay).¹⁰

FUNCTIONAL HIT ASSAY

In several cases, the ELISA results were confirmed by means of a functional HIT assay (HITAlert, Diapharma) performed at a reference laboratory in accordance with the manufacturer's instructions.¹¹ In brief, platelet-rich plasma was prepared from blood samples obtained from volunteer donors with group O blood. The platelet-rich plasma was incubated in five tubes that contained the following substances: calcium ionophore, heparin (0.3 U per milliliter), patient serum, patient serum plus heparin (0.3 U per milliliter), and patient serum plus an excess of heparin (100 U per milliliter). A previously tested serum sample from a patient with a confirmed diagnosis of HIT was used as a positive control (Fig. 1A). A positive threshold of more than 8% platelet activation was applied in accordance with the manufacturer's recommendations, providing a sensitivity of 78% and specificity of 98% when used to confirm the diagnosis of HIT. Data were analyzed with the use of a flow cytometer (CytoFlex, Beckman Coulter).

ADDITIONAL SEROLOGIC AND ANTIBODY TESTS

A multiplexed electrochemiluminescence assay (Meso Scale Discovery) was used, as described previously,¹² to measure serum levels of antibodies to SARS-CoV-2 antigens, including spike protein, receptor-binding domain (RBD), and nucleocapsid protein; levels of functional antibodies that inhibit the interaction of angiotensin-converting-enzyme 2 (ACE2)-receptor protein with spike protein and RBD of SARS-CoV-2; and levels of antibodies to spike protein of seasonal coronaviruses HCoV-OC43, HCoV-HKU1, HCoV-HL63, and HCoV-229E.

RESULTS

PATIENT CHARACTERISTICS

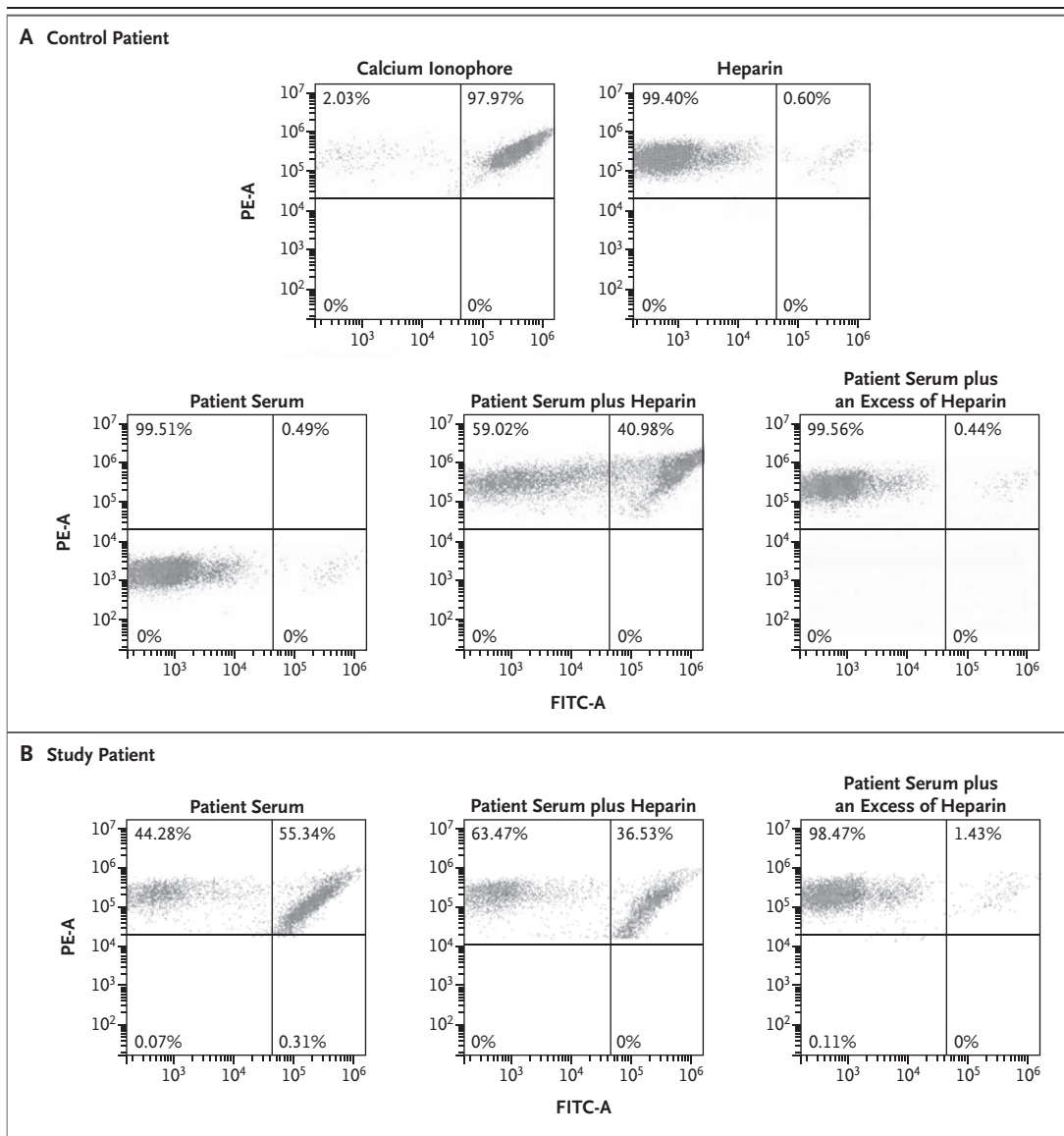
Among the 23 patients included in this study, the median age was 46 years (range, 21 to 77), with 16 patients (70%) younger than 50 years. Fourteen patients (61%) were female. All the patients were reported as previously fit and well by referring hospitals, with no history of a medical condition or use of a medication likely to precipitate thrombosis, except for 1 patient

who had a history of deep venous thrombosis and 1 patient who was known to be taking the combined oral contraceptive pill. All the patients had received the first dose of the ChAdOx1 nCoV-19 vaccine 6 to 24 days (median, 12 days) before presentation. Mild bruising and petechiae were evident in some patients. Secondary cerebral hemorrhage was noted in some patients who had cerebral venous thrombosis. The 1 patient who did not present with thrombosis had clinically significant bruising but no other hemorrhagic manifestations.

The clinical and laboratory features of the patients are summarized in Table 1. Of the 22 patients who presented with thrombosis, 13 had clinical features consistent with cerebral venous thrombosis (1 with concurrent acute portal vein thrombosis and pulmonary embolism), 4 had pulmonary embolism (1 with concurrent deep venous thrombosis), 1 had deep venous thrombosis and bilateral adrenal hemorrhage, 2 had an ischemic stroke affecting the middle cerebral artery territory, and 2 had portal vein thrombosis (1 with concurrent acute myocardial infarction and 1 with evidence of concurrent acute aortic thrombosis on imaging). Additional thrombosis events associated with progression occurred in patients who received platelet transfusions or heparin-based therapy at presentation. Within the entire cohort, 7 patients (30%) died. Results of a postmortem evaluation, available for 1 patient, showed evidence of thrombosis in many small vessels, especially vessels in the lungs and intestine, cerebral veins, and venous sinuses, as well as evidence of extensive intracerebral hemorrhage.

LABORATORY TESTING

All the patients had a negative SARS-CoV-2 polymerase-chain-reaction assay at presentation (data not shown). The 10 patients with samples available for testing had a negative SARS-CoV-2 serologic test for antibodies to nucleocapsid protein, a finding that ruled out recent exposure to SARS-CoV-2. In all 10 patients, levels of antibodies to spike protein and RBD of SARS-CoV-2 were within the range seen in recipients of one dose of the ChAdOx1 nCoV-19 vaccine, and levels of antibodies to seasonal coronaviruses were within the range seen in recipients of the ChAdOx1 nCoV-19 vaccine and in the general population. Levels of functional antibodies that



inhibit the interaction of ACE2-receptor protein with spike protein and RBD of SARS-CoV-2 were also within the range seen in recipients of one dose of the ChAdOx1 nCoV-19 vaccine (Goldblatt D; personal communication).

Thirteen patients had low fibrinogen levels as determined with the method of Clauss (range, 0.3 to 4.5 g per liter; normal range, 1.5 to 4.0). The D-dimer levels were much higher than would be expected in patients with acute venous thromboembolism (median, 31,301 fibrinogen-equivalent units [FEU]; range, 5000 to 80,000). No other relevant laboratory tests were positive, including tests for thrombophilia, antinuclear antibodies, extractable nuclear antigen, and antiphos-

pholipid antibodies (data not shown). A test for lupus anticoagulant was positive in 5 of the 10 patients for whom results were available, but in the context of severe coagulopathy and negative tests for anticardiolipin antibodies and anti- β_2 -glycoprotein 1b antibodies, these results were considered to be unreliable.

In all 23 patients, the ELISA for anti-PF4 antibodies was performed on a sample obtained before the administration of heparin-based therapy. Although HIT testing with the HemosIL AcuStar HIT IgG assay was negative in all 9 patients who were tested, an ELISA for anti-PF4 antibodies was positive in 22 of the 23 patients. One patient — who presented 10 days after vac-

Figure 1 (facing page). Flow Cytometric Analysis of Results of a Functional HIT Assay in a Control Patient and a Patient in the Study.

Shown is the flow cytometric analysis of results of a functional heparin-induced thrombocytopenia (HIT) assay (HITAlert, Diapharma) performed on a serum sample from a control patient with a confirmed diagnosis of HIT (Panel A) and on a serum sample from a patient included in the study (Panel B). Platelets from a volunteer donor with group O blood are incubated in five tubes containing the following substances: calcium ionophore, heparin (0.3 U per milliliter), patient serum, patient serum plus heparin (0.3 U per milliliter), and patient serum plus an excess of heparin (100 U per milliliter). In the analysis of the control sample (Panel A), donor platelets show reactivity in the presence of calcium ionophore, with 98% of platelets positive for both anti-CD41-PE and anti-annexin V-FITC conjugated antibodies (data are shown in the upper right quadrant of each plot); reduced reactivity in the presence of heparin (0.3 U per milliliter), with only 0.6% of CD41-positive platelets also positive for annexin V; reduced reactivity in the presence of patient serum, with only 0.5% of platelets activated; reactivity in the presence of patient serum plus heparin (0.3 U per milliliter), with 41% of platelets activated; and reduced reactivity in the presence of patient serum plus an excess of heparin (100 U per milliliter), with 0.4% of platelets activated, as compared with 41% with patient serum plus heparin in a physiologic dose. In the analysis of the study sample (Panel B), donor platelets show reactivity in the presence of patient serum, with 55% of platelets activated; reactivity in the presence of patient serum plus heparin (0.3 U per milliliter), with 37% of platelets activated; and reduced reactivity in the presence of patient serum plus an excess of heparin (100 U per milliliter), with 1% of platelets activated. FITC denotes fluorescein isothiocyanate, and PE phycoerythrin.

cination with cerebral venous thrombosis, thrombocytopenia, and a high D-dimer level and was not clinically distinguishable from the remaining cohort — had a negative ELISA (Life-codes PF4 IgG assay) and functional HIT assay. However, the tested sample had been obtained 5 days after presentation, after the patient had received several platelet transfusions. Another patient — who presented 12 days after vaccination with deep venous thrombosis and bilateral adrenal hemorrhage but with a high D-dimer level and a low fibrinogen level, with no evidence of an alternative diagnosis — had an equivocal result on the ELISA (a level of 0.156 OD on the Asserachrom HPIA IgG assay).

A functional HIT assay performed to confirm the ELISA result was positive in 5 of the 7 patients who were tested. These findings confirmed

the presence of platelet activation similar to that seen in patients with HIT (Fig. 1B), as measured by the addition of donor platelets to patient serum in the absence of heparin. This effect was not increased with the addition of heparin in physiologic doses but was fully suppressed with the addition of an excess of heparin. A summary of our recommendations for testing and treatment, based on our current understanding of the syndrome, is shown in Figure 2.

DISCUSSION

The rapid approval and subsequent global rollout of vaccines against SARS-CoV-2 has inevitably resulted in reports of adverse events after receipt of the vaccine. Most adverse events reported thus far have been associated with risks similar to background risks in the general population and have not raised concerns. However, for very rare events with complex diagnostic algorithms, the background risks may be difficult to measure or interpret.

We report the detection of anti-PF4 antibodies, unrelated to the use of heparin therapy, in a mostly young, generally healthy cohort of patients presenting with acute atypical thrombosis, primarily involving the cerebral veins, and concurrent thrombocytopenia. All the patients had D-dimer levels at presentation that were much higher than would be expected in patients with acute venous thromboembolism¹³ and are typically seen in patients with cancer.¹⁴ The very conservative D-dimer cutoff used in our algorithm, of 4000 FEU, was chosen to ensure that cases were not missed and were considered for further testing, because there is a possibility that a spectrum of severity in this syndrome could be missed otherwise. In all the patients, manifestations occurred 6 to 24 days after the administration of the first dose of the ChAdOx1 nCoV-19 vaccine.

HIT is a progressive thrombotic condition that can cause both venous and arterial thrombosis, typically 5 to 14 days after exposure to heparin. It is more common in female patients, particularly those who receive unfractionated heparin during cardiac surgery, as well as in patients who receive heparin after surgery, especially cardiac and orthopedic procedures.¹⁵ Diagnosis is confirmed by the presence of anti-PF4 antibodies.^{16,17}

Table 1. Clinical and Laboratory Characteristics of the 23 Patients in the Study.*

Patient Number (Sex, Age in yr)	Time from Vaccination to Admission days	Platelet Count $\text{cells} \times 10^9 / \text{liter}$	PT sec	APTT sec	Fibrinogen g/liter	D-Dimer FEU	HemosIL AcuStar HIT IgG Assay	Asserachrom HPIA IgG Assay	Lifecodes PF4 IgG Assay	Functional HIT Assay	Clinical Features	Outcome
Ref	—	150–400	10.0–12.0	25.0–37.0	1.5–4.0	0–550	Neg	≤ 0.238	<0.40	Neg	—	—
1 (F, 30)	13	27	1.1†	35.0	2.5	16,280	Neg	0.776	ND	Pos	CVT, PVT, PE, ischemic bowel with infarction	Alive
2 (F, 55)	6	11	13.1	1.0†	1.1	26,689	ND	1.310	ND	ND	PVT, AAT, ICH	Died
3 (F, 26)	12	64	1.1†	1.1†	3.2	>5,000	ND	ND	2.45	ND	CVT	Alive
4 (F, 52)	10	31	15.0	35.0	1.2	37,250	ND	ND	2.26	ND	Post mortem: thrombosis in the lungs and intestine, CVT, ICH	Died
5 (M, 38)	14	16	12.8	30.8	1.2	45,229	Neg	ND	2.84	Neg	Extensive bilateral PE with heart strain	Died
6 (F, 49)	15	14	1.4†	36.0	1.3	39,049	Neg	0.297	ND	ND	CVT, IJVT, SAH	Alive
7 (M, 25)	9	19	1.2†	1.1†	1.3	ND	ND	0.297	ND	ND	CVT	Died
8 (M, 32)	19	87	14.1	26.7	1.7	ND	Neg	1.440	ND	ND	CVT	Alive
9 (F, 35)	9	65	13.2	28.7	2.2	10,316	Neg	1.070	ND	ND	CVT	Alive
10 (M, 77)	8	ND	13.1	23.0	2.6	6,018	Neg	1.640	ND	ND	PE	Alive
11 (M, 66)	12	34			2.1	10,388	Neg	0.156	ND	ND	DVT, adrenal hemorrhage	Alive
12 (M, 34)	14	23	14.8	22.0	0.7	37,000	Neg	ND	Pos	ND	CVT	Alive
13 (M, 54)	10	71	13.5	32.7	1.2	80,000	ND	ND	0.76	ND	PVT, MI	Died
14 (F, 71)	14	17	1.4†	1.3†	0.8	>20,000	Neg	ND	Pos	ND	Hemorrhagic symptoms only	Alive
15 (F, 22)	10	100	11.1	23.6	3.0	>10,000	ND	ND	1.40	ND	CVT, ICH	Died
16 (F, 39)	10	57	1.2†	0.9†	4.4 (derived)	>5,000	ND	ND	1.40	ND	MCA infarct	Alive

17 (F, 70)	17	28	1.1†	1.4†	3.8 (derived)	>5,000	ND	ND	Pos	ND	PE (saddle embolism) with cardiac arrest, DVT in the leg	Alive
18 (M, 21)	10	113	1.3†	0.8†	1.0	22,903	ND	ND	2.80	Pos	MCA infarct	Alive
19 (F, 46)	14	7	1.1†	1.1†	1.1	31,301	ND	ND	>3.00	ND	CVT	Alive
20 (F, 32)	12	98	1.5†	1.7†	<0.4	6,574	ND	ND	2.17	Pos	CVT	Died
21 (M, 48)	14	16	1.2†	1.0†	1.2	62,342	ND	ND	2.45	Pos	CVT	Alive
22 (F, 49)	24	61	1.3†	1.0†	4.5	71,859	ND	ND	>3.00	Pos	PE	Alive
23 (F, 46)	10	36	1.4†	1.4†	0.7	>20,000	ND	ND	Neg	Neg	CVT	Alive

* AAT denotes acute aortic thrombosis, APTT activated partial thromboplastin time, CVT cerebral venous thrombosis, DVT deep venous thrombosis, FEU fibrinogen-equivalent units, HIT heparin-induced thrombosis, ICH intracerebral hemorrhage, IJVT internal jugular vein thrombosis, MCA middle cerebral artery, ND not done, Neg negative, OD optical density units, PE pulmonary embolism, Pos positive, PT prothrombin time, PVT portal vein thrombosis, Ref reference range, and SAH subarachnoid hemorrhage.

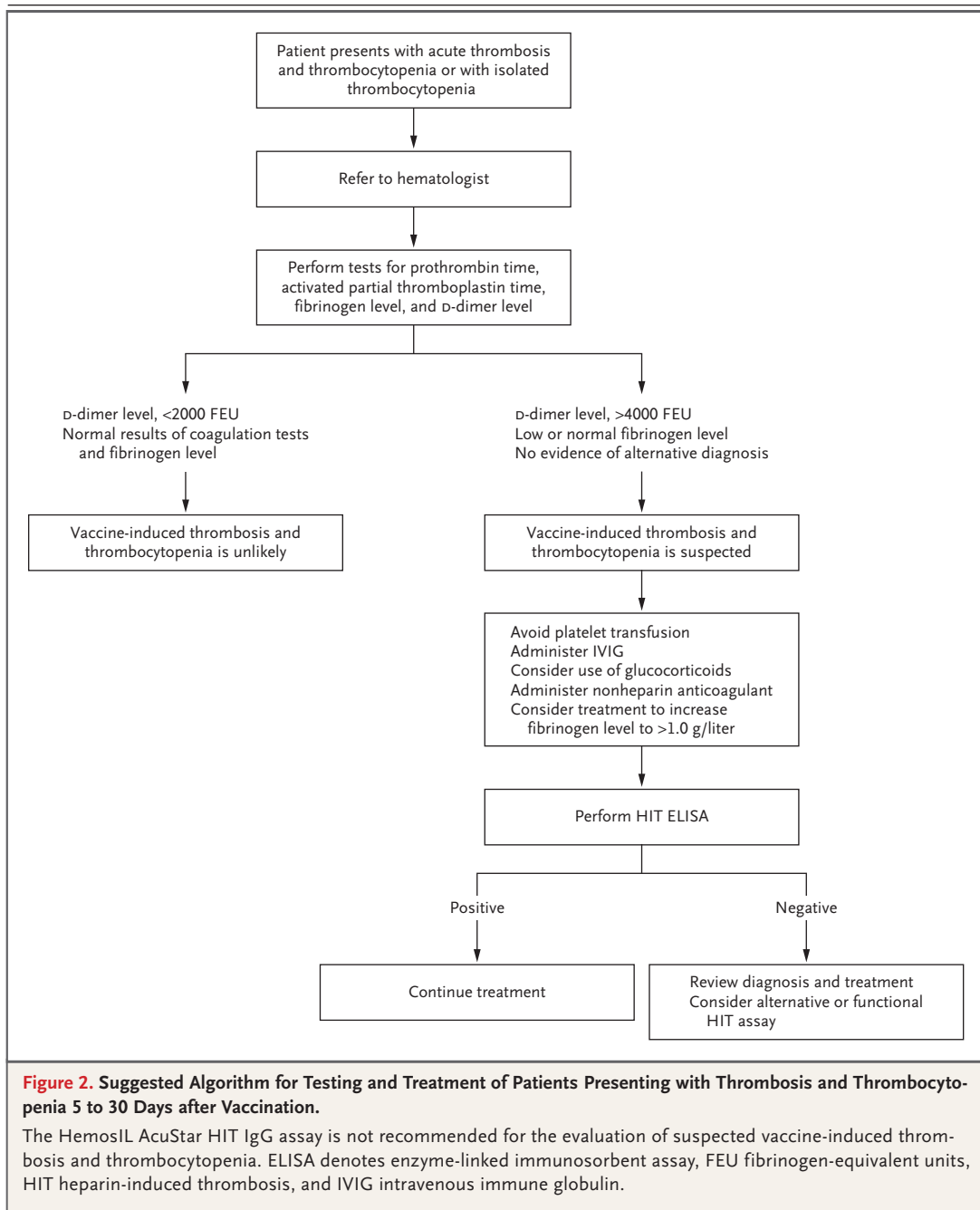
† The patient's value is expressed as a ratio of the mean normal value. The reference range for the PT ratio is 1.0 to 1.2 and for the APTT ratio is 0.8 to 1.2.

Data describing the rare detection of pathologic anti-PF4 antibodies unrelated to the use of heparin therapy are limited.^{18,19} Furthermore, the analysis of anti-PF4 antibodies appears to be specific to the given assay. In our study, confirmation of ELISA results for anti-PF4 antibodies was undertaken with the use of a functional HIT assay. The clinical features of this vaccine-induced syndrome are more typical of those seen in patients with HIT who have early reexposure to heparin, including severe thrombocytopenia, aggressive thrombosis, and disseminated intravascular coagulation.²⁰

The risk of thrombocytopenia and the risk of venous thromboembolism after vaccination against SARS-CoV-2 do not appear to be higher than the background risks in the general population, a finding consistent with the rare and sporadic nature of this syndrome. Furthermore, headaches, fevers, and muscle aches have occurred after vaccination for 48 to 72 hours in some patients. The events reported in this study appear to be rare, and until further analysis is performed, it is difficult to predict who may be affected. The symptoms developed more than 5 days after the first vaccine dose, reflecting an immunologic pattern similar to that of HIT.

We have identified a novel mechanism and pathophysiological basis that prompts careful consideration of treatment. Avoidance of platelet transfusions is critical, because such treatment would provide a substrate for further antibody-mediated platelet activation and coagulopathy. The exact nature of these pathologic antibodies has not been characterized, but they appear to be of the IgG subtype, and platelet activation can be completely abrogated with an excess of heparin, as seen in classic HIT. Identification of the mechanism through which the vaccine could trigger the formation of these pathologic antibodies would require further study. An understanding of the precise pathophysiological mechanism may allow for more targeted therapeutic interventions.

Although evidence does not yet suggest that the use of heparin will exacerbate this condition, pending further data, we would recommend considering anticoagulation with the use of a non-heparin anticoagulant agent, such as argatroban, danaparoid, fondaparinux, or direct oral anticoagulants. Intravenous immune globulin (IVIG) has been used successfully in the treat-



ment of patients with “spontaneous” autoimmune HIT, which is the closest comparison to this vaccine-induced syndrome, and IVIG would be expected to have direct antibody-mediated toxic effects.²¹⁻²³ Plasma exchange with plasma rather than albumin could also be effective in temporarily reducing levels of pathologic antibodies and providing some correction of the coagulopathy in terms of the hypofibrinogenemia.

A suggested algorithm for identification of vaccine-induced thrombosis and thrombocytopenia is presented and can be adapted as we generate further information. The combination of thrombosis and an apparent consumptive coagulopathy poses a dilemma with respect to the benefits and risks associated with aggressive anticoagulation. This dilemma is especially relevant in patients with cerebral venous thrombosis,

in whom bleeding could be catastrophic but withholding anticoagulation could be equally harmful. It is unclear whether delaying aggressive anticoagulation until after initial disease control with IVIG or plasma exchange is warranted, but mortality among patients with cerebral venous thrombosis appears to be higher than expected, so early treatment decisions are likely to be critical. There is no evidence that heparin alternatives are required; however, in view of the similarity of this syndrome to conventional HIT, alternatives could be considered until further data are available.

In all cases reported to date, this syndrome of thrombocytopenia and venous thrombosis appears to be triggered by receipt of the first dose of the ChAdOx1 nCoV-19 vaccine. Although there have been a few reports of patients with symptoms consistent with this clinical syndrome after the receipt of other vaccines against SARS-CoV-2, none have yet been confirmed to fulfill the diagnostic criteria, specifically the presence of thrombocytopenia, thrombosis, a very high D-dimer level, and a low or normal fibrinogen level. Furthermore, in Israel, where two doses of the BNT162b2 vaccine (Pfizer–BioNTech) have been provided to more than 4 million people, no cases of this rare syndrome have been reported.

Although natural SARS-CoV-2 infection has been associated with thromboembolic phenomena, those events differ from the specific syndrome described in this study.

The risk of Covid-19 remains a serious public health consideration worldwide, and vaccination against SARS-CoV-2 provides critical protection.²⁴ There is a substantial risk of ascertainment bias when associating adverse clinical events with vaccination; however, the syndrome described in this study has a combination of clinical and laboratory features that is exceptional and has not been previously observed by any of the authors who are specialist hematologists or neurologists. Ongoing data collection and studies could help to establish whether and how the development of pathologic platelet-activating anti-PF4 antibodies, unrelated to the use of heparin therapy, could be associated with vaccination against SARS-CoV-2.

Disclosure forms provided by the authors are available with the full text of this article at NEJM.org.

We thank the following colleagues for their input: Drs. Sue Pavord, Michael Makris, Beverley Hunt, Nichola Cooper, Quentin Hill, Catherine Bagot, Rachel Rayment, Gary Benson, and Nicola Curry of the U.K. Expert Group, as well as Drs. Clare Wykes, Pratima Chowdury, Roopen Arya, Rashid Kazmi, Oliver Lomas, Claire Davis, Smita Sinha, Sophie Lees, Gillian Lowe, and Saleem Shafeek.

REFERENCES

- Price-Haywood EG, Burton J, Fort D, Seoane L. Hospitalization and mortality among Black patients and White patients with Covid-19. *N Engl J Med* 2020;382:2534-43.
- Grasselli G, Greco M, Zanella A, et al. Risk factors associated with mortality among patients with COVID-19 in intensive care units in Lombardy, Italy. *JAMA Intern Med* 2020;180:1345-55.
- Johns Hopkins Coronavirus Disease Resource Center. April 2021 (<https://coronavirus.jhu.edu>).
- Hodgson SH, Mansatta K, Mallett G, Harris V, Emary KRW, Pollard AJ. What defines an efficacious COVID-19 vaccine? A review of the challenges assessing the clinical efficacy of vaccines against SARS-CoV-2. *Lancet Infect Dis* 2021;21(2):e26-e35.
- Izda V, Jeffries MA, Sawalha AH. COVID-19: a review of therapeutic strategies and vaccine candidates. *Clin Immunol* 2021;222:108634.
- Greinacher A, Thiele T, Warkentin TE, Weisser K, Kyrle PA, Eichinger S. Thrombotic thrombocytopenia after ChAdOx1 nCoV-19 vaccination. *N Engl J Med*. DOI: 10.1056/NEJMoa2104840.
- Schultz NH, Sørvoll IH, Michelsen AE. Thrombosis and thrombocytopenia after ChAdOx1 nCoV-19 vaccination. *N Engl J Med*. DOI: 10.1056/NEJMoa2104882.
- Government of the United Kingdom. UK regulator confirms that people should continue to receive the COVID-19 vaccine AstraZeneca. March 18, 2021 (<https://www.gov.uk/government/news/uk-regulator-confirms-that-people-should-continue-to-receive-the-covid-19-vaccine-astrazeneca>).
- European Medicines Agency. COVID-19 vaccine AstraZeneca: benefits still outweigh the risks despite possible link to rare blood clots with low blood platelets. March 18, 2021 (<https://www.ema.europa.eu/en/news/covid-19-vaccine-astrazeneca-benefits-still-outweigh-risks-despite-possible-link-rare-blood-clots>).
- Liederman Z, Van Cott EM, Smock K, Meijer P, Selby R. Heparin-induced thrombocytopenia: an international assessment of the quality of laboratory testing. *J Thromb Haemost* 2019;17:2123-30.
- Garritsen HS, Probst-Kepper M, Legath N, et al. High sensitivity and specificity of a new functional flow cytometry assay for clinically significant heparin-induced thrombocytopenia antibodies. *Int J Lab Hematol* 2014;36:135-43.
- Johnson M, Wagstaffe HR, Gilmour KC, et al. Evaluation of a novel multiplexed assay for determining IgG levels and functional activity to SARS-CoV-2. *J Clin Virol* 2020;130:104572.
- BjØri E, Johnsen HS, Hansen J-B, Braekkan SK. D-dimer at venous thrombosis diagnosis is associated with risk of recurrence. *J Thromb Haemost* 2017;15:917-24.
- Paneesha S, Cheyne E, French K, Bacchu S, Borg A, Rose P. High D-dimer levels at presentation in patients with venous thromboembolism is a marker of adverse clinical outcomes. *Br J Haematol* 2006;135:85-90.
- Warkentin TE. Clinical picture of heparin-induced thrombocytopenia (HIT) and its differentiation from non-HIT thrombocytopenia. *Thromb Haemost* 2016;116:813-22.
- Juhl D, Eichler P, Lubenow N, Strobel U, Wessel A, Greinacher A. Incidence and clinical significance of anti-PF4/heparin antibodies of the IgG, IgM, and IgA class in 755 consecutive patient samples referred for diagnostic testing for heparin-

- induced thrombocytopenia. *Eur J Haematol* 2006;76:420-6.
17. Selleng S, Selleng K, Friessecke S, et al. Prevalence and clinical implications of anti-PF4/heparin antibodies in intensive care patients: a prospective observational study. *J Thromb Thrombolysis* 2015;39:60-7.
 18. Hwang SR, Wang Y, Weil EL, Padmanabhan A, Warkentin TE, Pruthi RK. Cerebral venous sinus thrombosis associated with spontaneous heparin-induced thrombocytopenia syndrome after total knee arthroplasty. *Platelets* 2020 October 1 (Epub ahead of print).
 19. Warkentin TE, Makris M, Jay RM, Kelton JG. A spontaneous prothrombotic disorder resembling heparin-induced thrombocytopenia. *Am J Med* 2008;121:632-6.
 20. Rice L, Attisha WK, Drexler A, Francis JL. Delayed-onset heparin-induced thrombocytopenia. *Ann Intern Med* 2002;136:210-5.
 21. Mohanty E, Nazir S, Sheppard J-AI, Forman DA, Warkentin TE. High-dose intravenous immunoglobulin to treat spontaneous heparin-induced thrombocytopenia syndrome. *J Thromb Haemost* 2019; 17:841-4.
 22. Warkentin TE. High-dose intravenous immunoglobulin for the treatment and prevention of heparin-induced thrombocytopenia: a review. *Expert Rev Hematol* 2019;12:685-98.
 23. Irani M, Siegal E, Jella A, Aster R, Padmanabhan A. Use of intravenous immunoglobulin G to treat spontaneous heparin-induced thrombocytopenia. *Transfusion* 2019;59:931-4.
 24. Voysey M, Clemens SAC, Madhi SA, et al. Safety and efficacy of the ChAdOx1 nCoV-19 vaccine (AZD1222) against SARS-CoV-2: an interim analysis of four randomised controlled trials in Brazil, South Africa, and the UK. *Lancet* 2021; 397:99-111.

Copyright © 2021 Massachusetts Medical Society.